

# Arthroscopic capsular release for contracture of the wrist - a new technique



Gregory I. Bain, MBBS, FRACS.  
 Rik Verhellen, MD, Orthopaedic Fellow.  
 Modbury Public Hospital, Adelaide, South Australia, Australia.  
 Royal Adelaide Hospital, Adelaide, South Australia, Australia.  
 University of Adelaide, Adelaide, South Australia, Australia.

**Correspondence:**  
 Mr. Gregory I. Bain, MBBS, FRACS.  
 206 Melbourne Street,  
 North Adelaide, 5006,  
 South Australia, Australia.  
 Ph: (618) 8361 8399  
 Fax: (618) 8265 5157  
 E-mail: orthodoc@ctel.com.au

## INTRODUCTION

Following trauma or surgery to the wrist, stiffness of the wrist is common. Open radio-carpal and DRUJ capsular releases have been reported.<sup>6-7</sup> Arthroscopic release has been successfully used for contracture of the knee, shoulder and elbow, but has not been reported in the wrist.<sup>1-4</sup> Cadaveric studies have been performed to assess the safety of arthroscopic capsulotomy in the shoulder, but not in the wrist.<sup>5</sup>

The purposes of this paper are to :

- (1) to present a technique of arthroscopic capsular release of the wrist,
- (2) to assess the proximity of the neurovascular structures to the volar capsule.

## ANATOMICAL STUDY

The distance of the neurovascular structures from the radio-carpal capsule joint was measured on 10 transverse MRI images and two cadaveric wrist transverse sections. The results are presented in Fig 1 and Table 1.

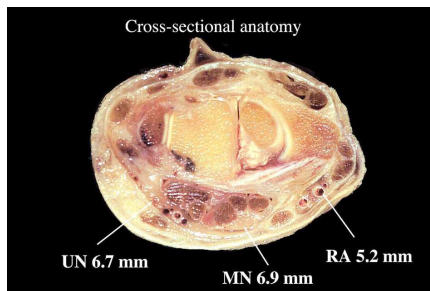


Fig 1: Cross-sectional anatomy of the radio-carpal joint with average distances to the major neurovascular structures.

| Structure | Range (mm) | Average (mm) |
|-----------|------------|--------------|
| Median N  | 4 - 9      | 6.9          |
| Ulnar N   | 4 - 9      | 6.7          |
| Radial A  | 3 - 7      | 5.2          |

Table 1: Distance from the radio-carpal joint capsule

## OPERATIVE TECHNIQUE

### Surgical technique

A diagnostic radiocarpal and midcarpal arthroscopy and debridement was performed with the hand suspended using a 2.7 or 1.9mm scope.<sup>8</sup> With the arthroscope in the 3-4 portal a hooked electrocautery probe was introduced from the 6R portal and advanced as far radially as possible. The ulno-triquetral and ulno-lunate ligament were left intact (Fig 2). The cautery was used to cut the volar capsule and was withdrawn to the ulnar side. The electrocautery device was then switched to the 1-2 portal. The capsule was cut until extra-carpal fat and FCR tendon were visualised. The section of the volar capsule included the short and long RL, RSL, RSC ligaments. A gentle closed manipulation was performed after the procedure.

The post-operative treatment consisted of full, unrestricted mobilisation of the wrist, assisted with a maraine wrist block. Physiotherapy assisted mobilisation was also performed.

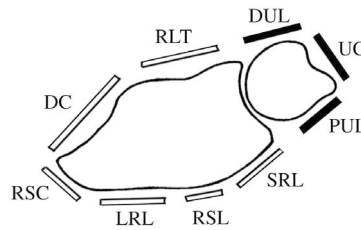


Fig 2: Drawing of the extent of the capsular release showing ligaments. Dorsal Capsule (DC), Radiolunotriquetral (RLT), Dorsal Ulnar (DUL), Ulnar Carpal (UC), Palmar Ulnar (PUL), Short Radiolunate (SRL), Radioscapholunate (RSL), Long Radiolunate (LRL), Radioscaphocapitate (RSC). Ligaments blackened (DUL, UC, PUL) are not sectioned

## CASES

Two patients were treated by arthroscopic capsular release for stiffness of the wrist refractory to conservative management. In both cases the restricted range of motion was due to capsular contracture. The measurements for pain (VAS 0-10), range of motion and grip strength are presented in Fig 3-5.

### Case 1:

A 23-year-old man who had an excision of a large right lunate intra-osseous ganglion and bone grafting from the ipsilateral distal radius metaphysis. His post-operative management consisted of 6 weeks of cast followed by mobilisation. Despite intensive physiotherapy, the wrist remained stiff, 9 months after surgery.

### Case 2:

The second patient was a 35-year-old woman who sustained an intra-articular distal radial fracture, which was treated by closed reduction and percutaneous K-wires. Five months following removal of the cast and extensive physiotherapy, the wrist remained stiff. Radiographs showed no intra-articular incongruity and 10° of dorsal angulation of the radius. Both patients were satisfied with the outcome and able to return to their previous occupations. There were no neurovascular complications. There was no clinical or radiological evidence of carpal instability at 6 months following surgery (Fig 6).

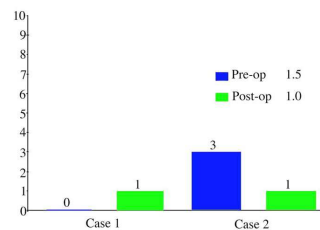


Fig 3: Visual Analogue Score for Pain. (Average pain scores in top right corner).

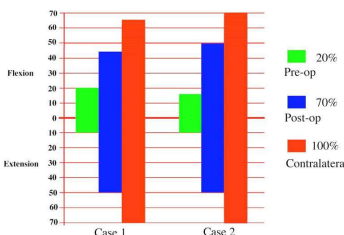


Fig 4: Range of Motion. (Percentages of contralateral wrist in top right corner).

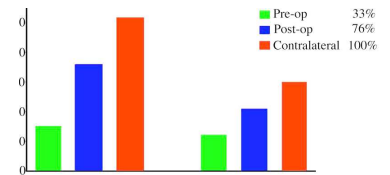


Fig 5: Grip-Strength. (Percentages of contralateral wrist in top right corner).

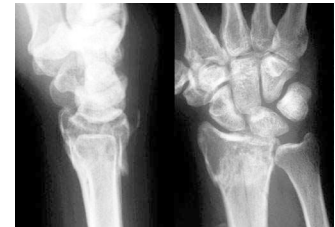

Fig 6: Post-operatively lateral and PA radiographs for case 2.

## DISCUSSION

**Functional range of motion:** as reported by Palmer and Werner, was achieved in both patients.<sup>9</sup> The arthroscopic technique is minimally invasive and allows an extensive release without the major dissection required for an open release.<sup>6</sup>

**Carpal instability:** Viegas et al. have reported that section of the RSC and RL ligaments alone does not lead to significant ulnar translation of the carpus, and that either the palmar ulnar or dorsal ulnar ligament complexes alone can prevent ulnar translation.<sup>10</sup> The arthroscopic capsulotomy leaves the palmar ulnar ligament and dorsal ulnar ligament complexes intact.

**Ideal patient:** The patient in which the joint stiffness is due to capsular contracture with a normal articular cartilage and joint congruity. Patients with displaced intra articular fractures, or carpal instability are unlikely to obtain good results. If the main problem is joint pain or generalised arthropathy then the results are less likely to be successful.

## CONCLUSION

Arthroscopic capsular release is technically feasible, safe and provides a significant improvement in range of motion using a minimally invasive technique.

**Acknowledgements:** Department of Anatomy, University of Adelaide for providing the cadaveric specimens. Ronald J Heptinstall for assistance in preparing this poster.

### References:

1. Richmond JC, al Assam M. Arthroscopic management of arthrofibrosis of the knee, including infrapatellar contraction syndrome. *Arthroscopy* 1991; 7 (2): 144-7.
2. Jones GS, Savoie FH. Arthroscopic capsular release of flexion contractures of the elbow. *Arthroscopy* 1993; 9(3):277-283.
3. Warner JJ, Answorth A, Marks PH, Wong P. Arthroscopic release for chronic, refractory adhesive capsulitis of the shoulder. *J Bone and Joint Surg* 1996; 78A: 1808-1816.
4. Warner JJ, Allen AA, Marks PH, Wong P. Arthroscopic release of post-operative capsular contracture of the shoulder. *J Bone and Joint Surg* 1997; 79A: 1151-8.
5. Zanotti RM, Kuhn JE. Arthroscopic capsular release for the stiff shoulder. Description of technique and anatomic considerations. *Am J Sports Med* 1997; 25(3): 294-8.
6. Watson HK, Turkelatub SH. Stiff joints. In: Green DP, ed. *Operative Hand Surgery*. New York: Churchill Livingstone, 1988; 537-552.
7. Kleinman WB, Graham TJ. Distal ulnar injury and dysfunction. In: Peimer CA, ed: *Surgery of the hand and upper extremity*. Mc Graw Hill, 1996; 667-710.
8. Bain GI, Richards RS, Roth JH. *Wrist Arthroscopy*. In: Lichtman D, Alexander, eds: *The wrist and its disorders*. Philadelphia: W.B. Saunders, 1997;151-168.
9. Palmer AK, Werner FEW, Murphy D, et al: *Functional wrist motion: a biomechanical study*. *J Hand Surg* 1985; 10A: 39-46.
10. Viegas SF, Patterson RM, Eng M, Ward K. *Extrinsic Wrist Ligaments in the Pathomechanics of Ulnar Translation Instability*. *J Hand Surg* 1995; 20A: 312-318.