



# THE DUBERT PROCEDURE FOR FIFTH CMC JOINT ARTHRITIS



Gregory I. Bain.  
P.M. Raghavan Unni  
Janak A. Mehta

Royal Adelaide Hospital, Adelaide, South Australia, Australia.  
Modbury Public Hospital, Adelaide, South Australia, Australia.

## INTRODUCTION

Arthritis produces pain and compromises the flexibility of the transverse metacarpal arch which impedes functional activities such as hand shaking and grasping a hammer.<sup>1</sup>

It has previously been treated with fifth metacarpal-hamate arthrodesis. Fifth metacarpal-hamate arthrodesis removes the normal mobility of the transverse metacarpal arch and loads the triquetrum-hamate joint. Excision arthroplasty of the fifth CMC joint: produces instability of the base of the fifth metacarpal, with potential for metacarpal shortening, malrotation and reduced grip strength.<sup>1,3,6</sup>

Dubert reported at the Helsinki IFFSH meeting in 1995 (Silastic Interposition graft: potential for instability and silicon synovitis) a technique of excision of the base of the fifth metacarpal with arthrodesis of it to the fourth metacarpal.<sup>9</sup> We report our result using a modification to this technique.

## OPERATIVE TECHNIQUE

### Exposure

Longitudinal incision over the fifth CMC joint and protect the dorsal branch of the ulnar nerve.

The periosteum is incised over the base of the fifth metacarpal and reflected proximally to expose the fifth CMC joint (enabling it to later be an interposition graft).

### Excision Arthroplasty of the metacarpal-hamate joint

The ECU tendon is retracted and the proximal 5mm of the fifth metacarpal is excised (Fig 1 and 2).

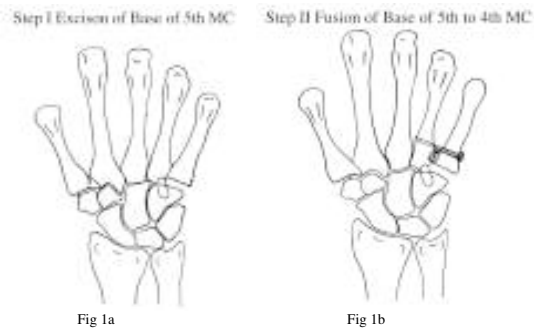


Fig 1. Fifth metacarpal basal excision and stabilisation with screw and supplemental bone graft.

### Arthrodesis of the base of the fourth to the fifth metacarpal

The articular facets of the fourth to fifth metacarpal joint are excised to subchondral bone (Fig 3). The bases of the fourth and fifth metacarpals are held with a bone holding clamp and care is taken to ensure a satisfactory rotation, alignment and length of the fifth metacarpal (Fig 4).

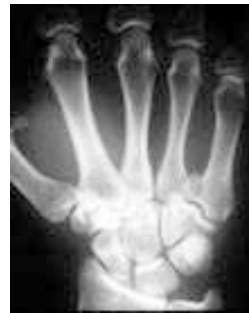

Fig 2. Pre-operative radiograph of case 2.

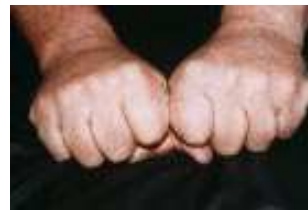

Fig 3. Preservation of the metacarpal arch and motion of the ulnar side of the hand in case 1.

One or two 2.7mm cortical lag screws are placed just distal to the CMC joint to fix the fifth to the fourth metacarpal. (Fig 5,6 and 7). Fluoroscopy is used to confirm the position of the fixation.<sup>10-11</sup> Autogenous cancellous bone graft is added. The dorsal periosteal/capsular flap is sutured to the volar joint capsule to act as an interposition graft between the fifth metacarpal and the hamate.

### Post-operative management

Ulnar gutter plaster of Paris splint is applied for 3 weeks followed by mobilisation with buddy taping.

## CORRESPONDENCE

Mr G.I. Bain, 206 Melbourne Street, North Adelaide,  
South Australia, Australia 5006.

Phone: (618) 8361 8399. Fax: (618) 8239 2237.

E-mail: orthodoc@ctel.com.au

## RESULTS

Three months post-operatively the pain score (0-10) of case 1 had improved from 6 to 0. Grip strength was 39 kg, compared to 50 kg for the dominant right side. He was able to comfortably perform activities of daily living and ride his motorbike.

Seven months postoperatively the pain score of case 2 had improved from 6 to 1. There was an improvement in grip strength from 28 kg to 50 kg, compared to 42 kg on the opposite nondominant wrist. He could now comfortably shake hands.

Both patients were satisfied and had a good cosmetic appearance without malalignment, malrotation or shortening of the fifth ray. The fifth metacarpal was stable and the transverse metacarpal arch preserved. There was flexion/extension on the ulnar side of the hand through the fourth CMC joint (Fig 4). Range of motion at the wrist was full and pain-free. Radiographs confirmed union between the fourth and fifth metacarpal bases (Fig 5). There were no infections or neurological complications.

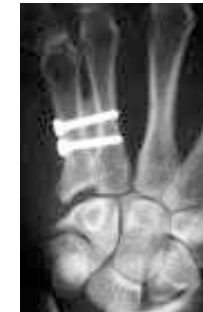

Fig 4. Postoperative radiograph of case 1.

## ADVANTAGES

- 1) Eliminates pain with resection of the base of the fifth metacarpal.
- 2) The inter-metacarpal fusion stabilises the fifth metacarpal, the transverse metacarpal arch and maintains length, rotation and alignment of the fifth ray.
- 3) The motion of the ulnar side of the hand is via the fourth CMC joint.

## REFERENCES

1. Gross W and Kilgore ES. Treatment of the fifth digit carpometacarpal arthritis with silastic prosthesis. *J Hand Surg* 1981;5:510-514.
2. Choudhri MB and Smith RJ. Fifth metacarpal-hamate arthrodesis for post-traumatic osteoarthritis. *J Hand Surg* 1984;9A:374-378.
3. Bain GJ and Elliott NE. The treatment of arthropathy of the carpometacarpal joints of the fifth finger. *JBJS* 1974;56A:1459-1465.
4. Mathiowetz VMS and Weber KBS. Reliability and validity of grip and pinch strength evaluations. *J Hand Surg* 1984;9A:222-226.
5. Barry CJ and Stark HH. Triquetrum arthroplasty of the fifth carpometacarpal joint for treatment of post-traumatic arthritis. *J Hand Surg* 1991;16A:520-524.
6. Black DM. Arthroplasty of the ulnar carpo-metacarpal joint. *J Hand Surg* 1987;12A:1071-1074.
7. Dubert Th, Desnoireaux P and Renaud B. "Stabilized" Arthroplasty of the Fifth Ray - Preliminary report. IFFSH, Helsinki 1995 (Abstract).
8. Bain, G.I., Hunt, J., Mehta, J.A., Operative Fluoroscopy in hand and upper limb surgery: First 100 cases. *Journal of Hand Surgery (Br)*. 1997; 22(B):5). 656-658