

Sigmoid Notch Osseous Reconstruction

Stephen K. Y. Tham, MBBS, FRACS

St. Vincent's Hospital Hand Unit, Melbourne

Dandenong Hospital, Dandenong, and

Victorian Hand Surgery Associates

Melbourne, Victoria, Australia

Gregory I. Bain, MBBS, FRACS

University of Adelaide

Modbury Public Hospital, and

Royal Adelaide Hospital, Adelaide

South Australia, Australia

ABSTRACT

The purpose of this article is to describe a technique of restoring stability or congruency to the distal radioulnar joint (DRUJ) by osteoplasty or osteotomy of the sigmoid notch, where abnormalities in the osseous anatomy have resulted in DRUJ instability. This technique addresses the osseous cause to DRUJ instability and avoids the need for complex soft tissue procedures to treat chronic volar instability or salvage procedures to treat dorsal instability of the DRUJ associated with an impacted fracture of the dorsal rim of the sigmoid notch.

Keywords: sigmoid notch, osteoplasty, osteotomy, DRUJ instability

HISTORICAL PERSPECTIVE

Historically, the treatment of distal radioulnar joint (DRUJ) instability has been directed toward restoration of its soft tissue stabilizers using various techniques¹ and has been the focus of most investigations. The stability of the DRUJ is provided by its soft tissue restraints and the osseous architecture of the sigmoid notch. These soft tissue restraints include the dorsal and volar radioulnar ligaments of the triangular fibrocartilage complex (TFCC), the extensor carpi ulnaris and its sheath, the pronator quadratus and other muscles, and the interosseous membrane.² Although the relative contribution of these structures to DRUJ stability remains controversial, it is generally agreed that the soft tissues, in particular the dorsal and volar radioulnar ligaments, are the prime stabilizers.^{3–9} Their structural importance also vary in forearm supination and pronation.

Pronation and supination involves rotation of the radius around the ulnar head and dorsal and palmar

gliding of the radius on the ulnar.^{3,4,10} The articular surfaces of the DRUJ are congruous in the midcoronal plane, but are not congruous in the transverse plane with a significant difference in their radii of curvature, with a mean radius of seat of the sigmoid notch of 19 mm and 10 mm for the ulnar seat.¹⁰ The osseous anatomy of the sigmoid notch has been estimated to provide 20% of DRUJ constraint,⁸ but there is significant variation in its osseous anatomy. Tolat et al¹⁰ described variations in the transverse plane with the “flat face” notch seen in 42% of their cadaveric wrists. Other variations include “ski-slope,” “C-type,” and “S-type” notch. An osteocartilaginous volar lip was seen in 98% of cadaveric specimens, and they suggested that the osteocartilaginous lip provides a stable buttress to volar dislocation of the ulna.

Volar instability of the DRUJ was first described by Dessault in 1777,¹¹ and there have been several reports on its diagnosis and management. Acute volar dislocations have been treated successfully by closed reduction and immobilization,^{12–15} although chronic instability has required reparative,¹⁶ reconstructive,^{17–19} or salvage²⁰ procedures.

Posttraumatic degenerative arthritis may develop as a result of chronic instability of the DRUJ or from posttraumatic changes to DRUJ congruency. It can be successfully treated by salvage procedures, such as Darrach, hemiresection interposition arthroplasty, or Sauve-Kapandji procedures; however, these procedures may result in reduced grip strength, painful instability of the ulnar shaft, and reossification.^{21,22}

Although reconstructive procedures are effective in the treatment of chronic posttraumatic DRUJ instability, persistent instability will occur if there is a deficient sigmoid notch.²³ In these cases, reconstruction of the deficient notch maybe required either alone or with soft tissue reconstruction. We are aware of 3 case reports of osseous reconstruction of the sigmoid notch to restore DRUJ stability.^{24–26}

Address correspondence and reprint requests to Gregory I. Bain, MBBS, FRACS, 196 Melbourne Street, North Adelaide, 5006 South Australia, Australia. E-mail: greg@gregbain.com.au.

■ INDICATIONS/CONTRAINDICATIONS

Osteoplasty or corrective osteotomy of the sigmoid notch is indicated when DRUJ instability is present, despite intact volar and dorsal radioulnar ligaments and associated with a dysplasticlike, flat sigmoid notch or with depressed fractures to the dorsal or volar margins of the sigmoid notch (Fig. 1).

A diagnosis of DRUJ instability is first considered on the basis of clinical history. Further suspicion is raised with examination of stability in pronation, midprone, and supination. However, radiological confirmation with axial computed tomographic (CT) images is necessary before a diagnosis can be made. This requires stress views in different positions of forearm rotation²⁷ and measured according to criteria from Mino et al,²⁸ where the ulnar head in a normal DRUJ should lie between 2 lines marking the dorsal and palmar borders of the radius. Plain radiographs, although necessary in the initial assessment, are unreliable methods of assessing static or dynamic DRUJ instability. Computed tomographic scans also allow assessment of the osseous contour of the sigmoid notch. As the anatomy of the sigmoid notch is quite variable, comparison with the normal other side may be necessary. The radius and sector angles of seat of the sigmoid notch and ulnar head may be determined by the method of tangents as described by af Ekestam and Hagert.³

The volar and dorsal radioulnar ligaments are the prime stabilizers of the DRUJ,⁸ and its status is increasingly being assessed by magnetic resonance imaging. Despite advances in image resolution, it has not reached a sufficient level of sensitivity to be considered the criterion standard for assessment of TFCC lesions^{29–31} and may need to be combined with wrist arthroscopy to exclude palmar and dorsal radioulnar ligament injuries.

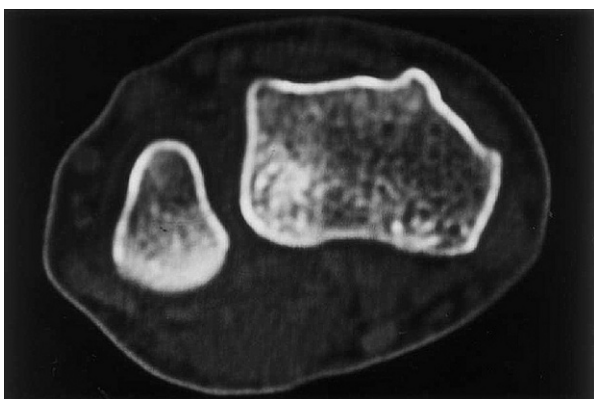


FIGURE 1. A preoperative axial CT scan of the left wrist in full supination shows a flat sigmoid notch with volar dislocation of the DRUJ. Reprinted with permission from Wallwork NA, Bain GI. Sigmoid notch osteoplasty for chronic volar instability of the distal radioulnar joint: a case report. *J Hand Surg.* 2001;26:454–459.

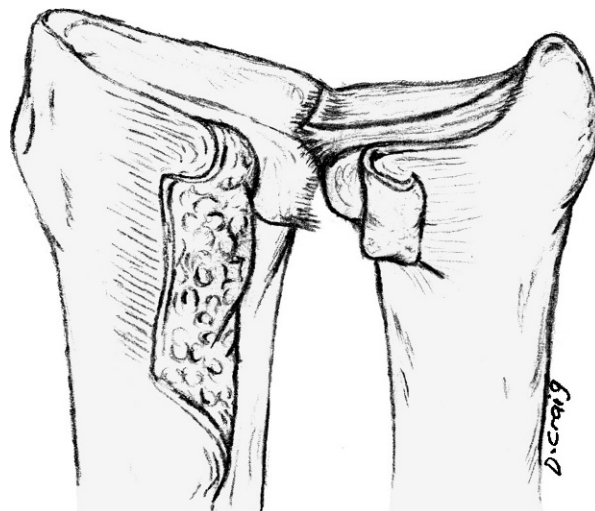


FIGURE 2. Volar exposure of the DRUJ. Reprinted with permission from Wallwork NA, Bain GI. Sigmoid notch osteoplasty for chronic volar instability of the distal radioulnar joint: a case report. *J Hand Surg.* 2001;26:454–459.

This procedure is contraindicated where instability is associated with degenerative arthritis of the DRUJ.

■ TECHNIQUE

Osteoplasty/Osteotomy of the Volar Rim of the Sigmoid Notch

The volar approach to the sigmoid notch²⁴ is through a longitudinal incision on the ulnar side of the wrist and dissected between the ulnar neurovascular bundle and

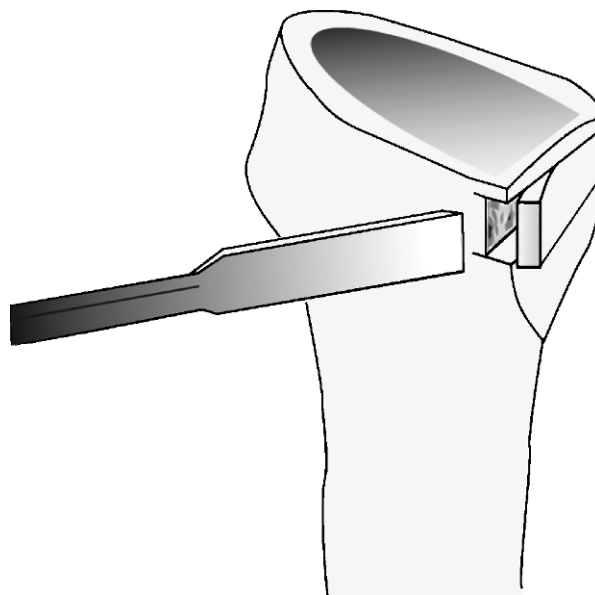


FIGURE 3. The sigmoid notch osteoplasty. Reprinted with permission from Wallwork NA, Bain GI. Sigmoid notch osteoplasty for chronic volar instability of the distal radioulnar joint: a case report. *J Hand Surg.* 2001;26:454–459.

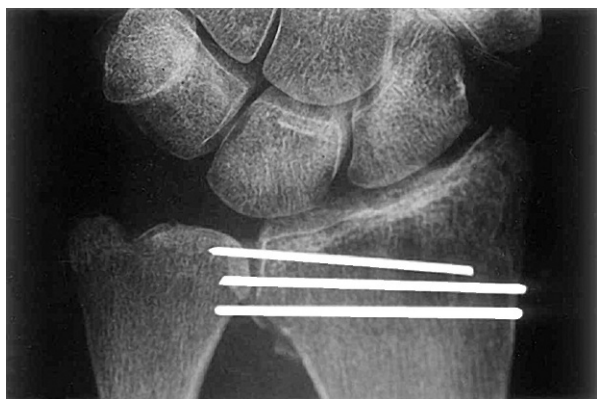


FIGURE 4. A postoperative radiograph with the Kirschner wires positioned in the radius. Reprinted with permission from Wallwork NA, Bain GI. Sigmoid notch osteoplasty for chronic volar instability of the distal radioulnar joint: a case report. *J Hand Surg.* 2001;26:454–459.

long flexor tendons.³² The pronator quadratus is released from the ulnar and reflected radially to expose the volar capsule of the DRUJ.

The volar capsule is then divided by a longitudinal incision 2 mm from its insertion into the radius and transverse incisions just distal to its attachment to the ulnar and just proximal to its insertion into the TFCC (Fig. 2). This exposes the palmar articular surface of the sigmoid notch and allows accurate placement of the osteotomy. The TFC is left intact so as not to further compromise stability.

Two transverse osteotomies are performed at the edges of the articular surface of the sigmoid notch (Fig. 3). The first is placed 2 mm proximal to the

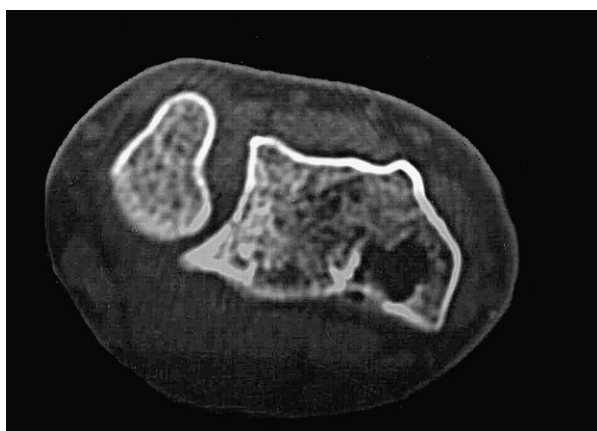

FIGURE 5. Eighteen months after surgery, an axial CT scan in full supination shows the augmentation of the volar lip of the sigmoid notch and reduction of the DRUJ. Reprinted with permission from Wallwork NA, Bain GI. Sigmoid notch osteoplasty for chronic volar instability of the distal radioulnar joint: a case report. *J Hand Surg.* 2001;26:454–459.

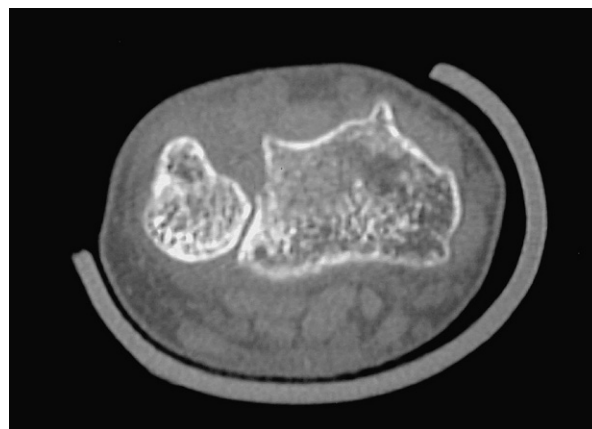


FIGURE 6. Preoperative CT scan showing reduced ulnar head with depressed fracture of dorsal lip of sigmoid notch.

radiocarpal joint and the second at the proximal articular margin of the sigmoid notch. A third longitudinal osteotomy is performed 5 mm radial to the sigmoid notch and parallel to it and advanced into the dorsal half of the radius. An osteotome is then used to lever the osseous flap in an ulnar direction, increasing the volar curvature of the sigmoid notch. As the osteotome is advanced, the radius and ulnar are separated. The volar radioulnar ligament remains intact and so is tightened as the osteocartilaginous flap is advanced ulnarly.

The resulting defect may be filled with a wedge-shaped bone graft from the volar radius or bone graft substitute. Three 1.1-mm Kirschner wires are advanced through the volar lip of the sigmoid notch and the graft to exit through the dorsoradial border of the radius (Fig. 4). The volar capsule is plicated, and the pronator quadratus is reattached to the ulnar. As the osteotomy is opened and the TFC remains intact, the joint becomes stable. Postoperative CT scan is demonstrated in Figure 5.

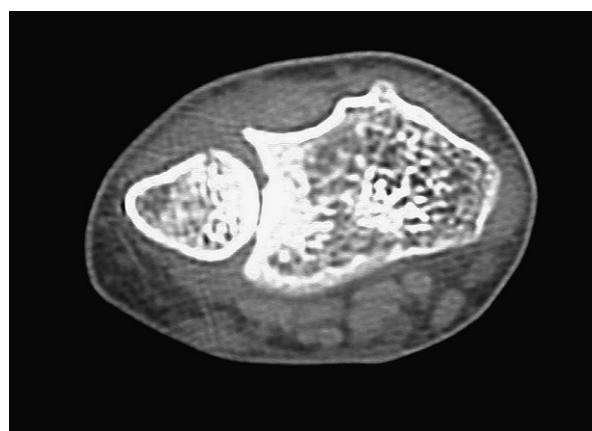


FIGURE 7. Twelve-month postoperative CT scan after osteotomy and bone graft of the dorsal lip of sigmoid notch.

Osteotomy for Depressed Fracture of Dorsal Rim Sigmoid Notch

The DRUJ in patients with dorsal dislocation of the ulnar head is held reduced in supination, and the dorsal approach to the sigmoid notch in these patients is performed with the forearm supinated and elbow flexed.

A longitudinal incision is made over the fourth extensor compartment. After retraction of the extensor communis tendons radially, the dorsal capsule of the DRUJ is incised proximal to the dorsal radioulnar ligament of the TFCC. Fluoroscopy may be required to identify the DRUJ as the floor of the fourth extensor compartment blends with the dorsal capsule. This will expose the sigmoid notch and depressed fracture of the dorsal rim. An osteotomy is then performed with an osteotome just radial to and on the sagittal plane along the length of the fracture. The osteotome is then used to carefully elevate the depressed articular surface of the sigmoid notch, restoring its concave articular surface. A wedge-shaped corticocancellous bone graft from the distal radius or bone graft substitute is inserted into the resulting defect. In our case report,²⁶ we did not find Kirschner wire fixation necessary because the bone graft substitute was stable after insertion. Preoperative and postoperative CT scans demonstrate the depressed dorsal lip of the sigmoid notch (Fig. 6) and its position after osteotomy and bone graft (Fig. 7).

■ COMPLICATIONS

Persistent instability needs to be avoided. Failure to obtain or maintain joint stability with the osseous reconstruction can theoretically occur. This can be caused by fragmentation, avascular necrosis, or non-union of the osteocartilaginous lip. Late arthrosis of the DRUJ may occur.

■ REHABILITATION

The forearm is placed in an above-elbow cast in full pronation (for osteoplasty/osteotomy of the volar rim) or supination (for osteoplasty/osteotomy of the dorsal rim) for 4 weeks. The cast is then removed, and physical therapy is commenced. Dynamic pronation and supination splints may be required to aid recovery of pronation or supination.

■ DISCUSSION

Distal radioulnar joint instability is most commonly associated with disruptions to its soft tissue restraints, and repair or reconstruction of these ligaments has been the mainstay of treatment. It is uncommonly associated with changes to the osseous anatomy of the sigmoid notch. In cases where the soft tissue restraints are intact,

osseous reconstruction by osteoplasty or osteotomy of the dorsal or volar rims may be considered.

■ REFERENCES

1. Bowers WH. The distal radioulnar joint. In: Green DP, ed. *Operative Hand Surgery*. New York, NY: Churchill Livingstone, 1993:973–1019.
2. Chidgey LK. Treatment of acute and chronic instability of the distal radio-ulnar joint. *Hand Clin*. 1998;14:297–303.
3. af Ekenstam F, Hagert CG. Anatomical studies on the geometry and stability of the distal radio ulnar joint. *Scand J Plast Reconstr Surg*. 1985;19:17–25.
4. Schuind F, An KN, Berglund L, et al. The distal radio-ulnar ligaments: a biomechanical study. *J Hand Surg [Am]*. 1991;16:1106–1114.
5. af Ekenstam F. Anatomy of the distal radioulnar joint. *Clin Orthop*. 1992;275:14–18.
6. Adams BD, Holley KA. Strains in the articular disk of the triangular fibrocartilage complex: a biomechanical study. *J Hand Surg [Am]*. 1993;18:919–925.
7. Kihara H, Short WH, Werner FW, et al. The stabilizing mechanism of the distal radioulnar joint during pronation and supination. *J Hand Surg [Am]*. 1995;20:930–936.
8. Stuart PR, Berger RA, Linscheid RL, et al. The dorso-palmar stability of the distal radioulnar joint. *J Hand Surg [Am]*. 2000;25:689–699.
9. Gofton WT, Gordon KD, Dunning CE, et al. Soft-tissue stabilizers of the distal radioulnar joint: an in vitro kinematic study. *J Hand Surg [Am]*. 2004;29:423–431.
10. Tolat AR, Stanley JK, Trail IA. A cadaveric study of the anatomy and stability of the distal radioulnar joint in the coronal and transverse planes. *J Hand Surg [Br]*. 1996;21:587–594.
11. Rose-Innes AP. Anterior dislocation of the ulna at the inferior radio-ulnar joint: case report, with a discussion of the anatomy of rotation of the forearm. *J Bone Joint Surg [Br]*. 1960;42-B:515–521.
12. Gale DW, Parmar H. Isolated, volar dislocation of the distal ulnar without an associated forearm fracture. *J R Coll Surg Edinb*. 1994;39:196–197.
13. Morrissy RT, Nalebuff EA. Dislocation of the distal radioulnar joint: anatomy and clues to prompt diagnosis. *Clin Orthop*. 1979;144:154–158.
14. Singletary EM. Volar dislocation of the distal radioulnar joint. *Ann Emerg Med*. 1994;23:881–883.
15. Schiller MG, af Ekenstam F, Kirsch PT. Volar dislocation of the distal radio-ulnar joint. A case report. *J Bone Joint Surg Am*. 1991;73:617–619.
16. Cheng SL, Axelrod TS. Management of complex dislocations of the distal radioulnar joint. *Clin Orthop*. 1997;341:183–191.
17. Kashyap S, Fein L. Surgical correction of recurrent volar

- dislocation of the distal radioulnar joint: a case report. *Clin Orthop*. 1991;266:85–89.
18. Fulkerson JP, Watson HK. Congenital anterior subluxation of the distal ulnar: a case report. *Clin Orthop*. 1978;131:179–182.
 19. Breen TF, Jupiter J. Tenodesis of the chronically unstable distal ulnar. *Hand Clin*. 1991;7:355–363.
 20. Darrach W. Forward dislocation of the inferior radio-ulnar joint, with fracture of the lower third of the shaft of the radius. *Ann Surg*. 1912;56:801–802.
 21. Bowers WH. Distal radioulnar joint arthroplasty: the hemiresection-interposition technique. *J Hand Surg [Am]*. 1985;10:169–178.
 22. George MS, Kiefhaber TR, Stern PJ. The Sauve-Kapandji procedure and the Darrach procedure for distal radio-ulnar joint dysfunction after Colles' fracture. *J Hand Surg [Br]*. 2004;29:608–613.
 23. Adams BD, Berger RA. An anatomic reconstruction of the distal radioulnar ligaments for posttraumatic distal radio-ulnar joint instability. *J Hand Surg [Am]*. 2002;27:243–251.
 24. Wallwork NA, Bain GI. Sigmoid notch osteoplasty for chronic volar instability of the distal radioulnar joint: a case report. *J Hand Surg [Am]*. 2001;26:454–459.
 25. Merrell GA, Barrie KA, Wolfe SW. Sigmoid notch reconstruction using osteoarticular graft in a severely comminuted distal radius fracture: a case report. *J Hand Surg [Am]*. 2002;27:729–734.
 26. Thomas J, Large R, Tham SK. Sigmoid notch osteotomy for posttraumatic dorsal dislocation of the distal radioulnar joint: a case report. *J Hand Surg [Am]*. 2006;31:1601–1604.
 27. Pirela-Cruz MA, Goll SR, Klug M, et al. Stress computed tomography analysis of the distal radioulnar joint: a diagnostic tool for determining translational motion. *J Hand Surg [Am]*. 1991;16:75–82.
 28. Mino DE, Palmar AK, Levinsohn EM. The role of radiography and computerized tomography in the diagnosis of subluxation and dislocation of the distal radioulnar joint. *J Hand Surg [Am]*. 1983;8:23–31.
 29. Potter HG, Asnis-Ernberg L, Weiland AJ, et al. The utility of high-resolution magnetic resonance imaging in the evaluation of the triangular fibrocartilage complex of the wrist. *J Bone Joint Surg Am*. 1997;79:1675–1684.
 30. Blazar PE, Chan PS, Kneeland JB, et al. The effect of observer experience on magnetic resonance imaging interpretation and localization of triangular fibrocartilage complex lesions. *J Hand Surg Am*. 2001;26:742–748.
 31. Tanaka T, Yoshioka H, Ueno T, et al. Comparison between high-resolution MRI with a microscopy coil and arthroscopy in triangular fibrocartilage complex injury. *J Hand Surg [Am]*. 2006;31:1308–1314.
 32. Pourgiezis N, Bain GI, Roth JH, et al. Volar ulnar approach to the distal radius and carpus. *Can J Plast Surg*. 1999;7:273–278.